


Skull Assessment Guide

FL - Forehead Length: Look at the front of the skull and determine if the forehead is Long (L) or Short (S). The forehead is roughly the area from the top of the eye socket to the part of the skull that begins to flatten. Visualize your own forehead and imagine the part between your eyebrows to where your hairline begins. This is the forehead. If this length is at least the length of the average thumb, we consider it to be Long (L).



SC - Sagittal Crest: Look at the top of the skull and determine if a sagittal crest is present (+) or absent (-). A sagittal crest is a ridge of bone that protrudes from the skull and runs on top of the skull from front to back.



BR - Brow Ridge: Look at the front of the skull and determine if a brow ridge is present (+) or absent (-). A brow ridge is a bone that runs the entire width of the skull just above the eyes (see arrow in photograph).

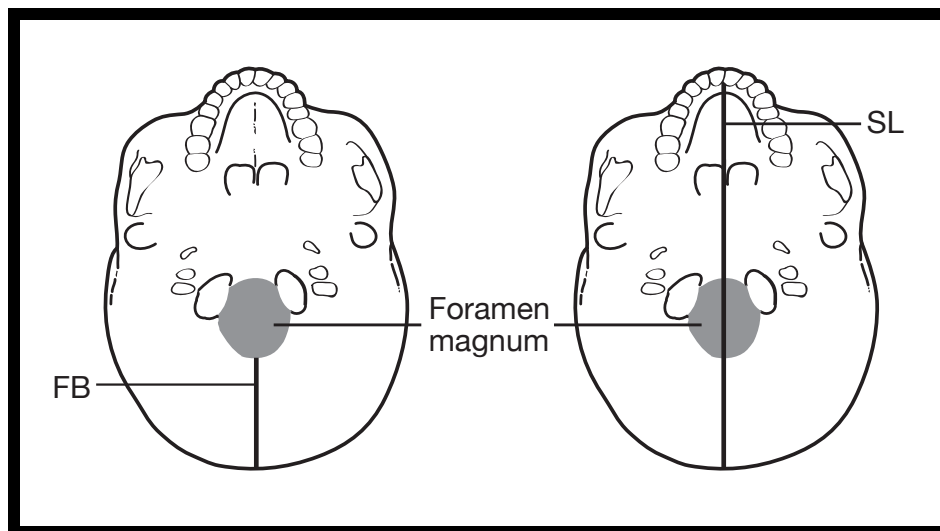
P/S - Prognathism/Snout: Look at the front of the skull and determine if it exhibits prognathism (+) or not (-). Prognathism refers to the protrusion of the mouth from the front of the skull. Animals with prognathism are thought of as having a 'snout'. To determine if a skull exhibits prognathism, press your fingers along the base of the nose opening (Anterior Nasal Spine) and rest it on the top of the maxilla (where the top teeth attach). If this area is greater than 1 index finger in width, then we consider the skull to exhibit prognathism.

Skull Assessment Guide



CL - Canines Long (and sharp): Look at the teeth in the top of skull and determine if the canines are long and sharp (+) or (-). The canines are sometimes referred to as ‘fangs’. They are the third pair of teeth from the front – in your mouth, your 2 front teeth and the next one in each direction are called ‘incisors’. The next tooth on either side is slightly pointy and called ‘canine’, but in many animals, like dogs and cats, these canines are very long and sharp. If the canines are not present in the skull, the cell in the table has been blackened out. If you notice that the canines are ‘fang-like’, we consider them to be long and sharp (+).

FB - Foramen Magnum Distance to Back (mm): Look at the underside of the skull and determine the distance between the foramen magnum and the back of the skull, measured in mm). The foramen magnum is the hole in the skull through which the spinal cord attaches to the brain. To determine this distance, place a ruler on the base of the skull, starting at the back most edge of the foramen magnum and measure the distance to the end of the skull (see diagram below).



Skull Assessment Guide

SL - Skull Length (mm): Look at the underside of the skull and determine the length of the skull (measured in mm). Place a ruler on the base of the skull (see diagram below) and measure the distance from the back of the skull to the end of the palate (roof of the mouth). Be sure to demonstrate this measurement to your students.

FMI - Foramen Magnum Index: Calculate the ratio using the Foramen Magnum Distance to Back (FB) and the Skull Length (SL). To do this for each skull, divide the value that you recorded for FB by the value that you recorded for SL, and fill in the corresponding box to the 3rd digit after the decimal point.

CC - Cranial Capacity: Look at the skull from the top and sides and estimate the number of average fists that would fit inside the cranium (the area of the skull where the brain is located). For these skulls, limit your estimate to 2, 3 or 4.